

Caso Clínico

Case Report

Banu Alicioglu*
Mert Saynak**

Metástases nas leptomeninges da espinal medula num doente com carcinoma de células escamosas do pulmão

Spinal leptomeningeal metastasis in a patient with squamous cell lung cancer

Recebido para publicação/received for publication: 08.06.19
Aceite para publicação/accepted for publication: 08.07.23

Resumo

As metástases nas leptomeninges da espinal medula ocorrem raramente nos tumores sólidos e o prognóstico é bastante reservado. Os adenocarcinomas e os carcinomas de pequenas células são os grupos histológicos mais envolvidos no que se refere aos tumores pulmonares. Um homem de 58 anos com história de carcinoma de células escamosas do pulmão com inversão mediastínica e metástases cerebrais apresenta lombalgias e fraqueza em ambos os membros inferiores. A RMN da coluna vertebral revelou espessamento na espinal medula e múltiplos nódulos do grupo das fibras da cauda equina. Tanto quanto sabemos, trata-se do segundo caso relatado de carcinoma pulmonar de células escamosas que apresenta metástases nas leptomeninges da espinal medula.

Rev Port Pneumol 2008; XIV (6): 875-879

Palavras-chave: Espinal medula, leptomeninges, metástases, ressonância magnética nuclear.

Abstract

Spinal leptomeningeal metastasis occurs rarely in solid tumors, and the prognosis is extremely poor. Adenocarcinomas and small-cell carcinomas are the most common histological type detected among lung tumors. A 58-year-old man with a history of squamous-cell lung carcinoma with mediastinal invasion and brain metastasis was examined because of his low back pain and weakness in both lower limbs. Spinal MRI revealed subpial enhancement in the spinal cord; and innumerable nodules with thickening of the cauda equina fibres. To our knowledge, this is the second reported case of squamous cell lung cancer with spinal leptomeningeal metastasis.

Rev Port Pneumol 2008; XIV (6): 875-879

Key-words: Spinal, leptomeningeal, metastasis, lung cancer, magnetic resonance imaging.

* Trakya University Medical Faculty, Radiology and Anatomy departments, Edirne/TURKEY

** Trakya University Medical Faculty, Radiation Oncology department, Edirne/TURKEY

Adress for correspondance:

Banu ALICIOGLU

Fatih mah. 4.cad 43.sok. Ziraatliiler Sitesi B Blok no:8

22030, Edirne/TURKEY

Tel: 90 284 2363089

GSM: 90 532 3660070

E-mail: banualicioglu@trakya.edu.tr; banu_alici@yahoo.com

Introduction

Leptomeningeal metastases are being recognized with increasing frequency in last decades as the result of improved therapy of systemic malignancies. Increased the life span of cancer patients allow the late expression of leptomeningeal metastases. Advances in technology increase the sensitivity of neuroradiological imaging enables to diagnose the leptomeningeal metastases¹⁻⁴. Another reason is that the meninges are a sanctuary for many cytotoxic agents that have difficulty crossing the intact blood-CSF barrier, therefore tumor cells in the subarachnoid tumor are not adequately treated and may proliferate⁴. Finally infiltration of the leptomeninges by any malignancy is a serious complication that results in substantial morbidity and mortality².

In the present report we describe a patient with squamous cell lung cancer, who developed a leptomeningeal infiltration in cauda equina fibers and spinal cord.

Case report

A 58 years-old male patient was evaluated for his treatment management with the diagnosis of low-differentiated squamous cell lung cancer in our clinic in february 2007. He had a mass in the right lung with mediastinal invasion and multiple mediastinal lymphadenopathies in the right inferior paratracheal region. But no other metastases had been detected on abdominal computed tomography (CT), cranial magnetic resonance imaging (MRI), whole body positron emission tomography and skeletal surveys. With the diagnosis of a locally advanced NSCLC he had an induction chemotherapy with cisplatin (75mg/m²)

and docetaxel (75mg/m²). After three cycles of combination chemotherapy, a total dose of 64Gy in 32 fractions external adjuvant radiotherapy to the right lung and mediastinum was performed combined with two cycles of cisplatin (60mg/m²). Following chemoradiotherapy, thorax CT revealed, minimal regression in the mass and mediastinal lymph nodes. Five months later he presented with vertigo complaints, cranial MRI revealed multiple metastatic nodules with mass effect in the right superior temporal gyrus, left frontoparietal, frontal and parietal lobes. There was not leptomeningeal enhancement. 30 Gy in 10 fractions palliative whole-brain RT was performed for his brain metastases. After one month, he had low back pain referring to both legs, and weakness in his legs complaints. A spinal MRI was performed to exclude bone metastasis. Innumerable small hypointense nodules were detected along the cauda equina fibers on T2 weighted sagittal scan (Fig. 1A). After the administration of gadolinium chelate, diffuse innumerable nodular enhancement and thickening in the nerve fibers was seen. Small subpial metastatic nodules were also detected in the lower medulla spinalis (Figs. 1B and 2). 17,5 Gy in 5 fractions external palliative radiotherapy was performed to T2-T12 and L1-S2 spinal areas using a posterior field. Unfortunately he died in January 2008.

Discussion

Primary CNS malignancies especially medulloblastoma and CNS lymphoma are the most common cause of leptomeningeal metastases. Cancers such as leukemia, lymphoma, breast cancer, lung cancer, and mela-

METÁSTASES NAS LEPTOMENINGES DA ESPINAL MEDULA NUM DOENTE COM CARCINOMA DE CÉCULAS ESCAMOSAS DO PULMÃO

Banu Alicioglu, Mert Saynak

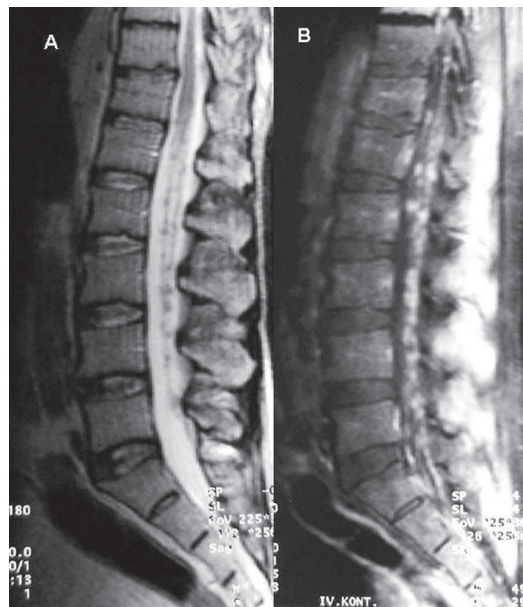


Fig. 1 – Sagittal T2-weighted (A) MRI scan shows small hypointense nodules in the cauda equina fibers. After the injection of the gadolinium, T1-weighted scan (B) shows extensive leptomeningeal metastases in the cauda equina. No vertebral metastasis was seen

noma frequently involve the leptomeninges². Although the availability of new diagnostic modalities, leptomeningeal carcinomatosis remains underdiagnosed and underestimated. Additionally, patients already diagnosed with brain metastases, symptoms and signs relating to the brain were attributed to these cerebral metastases³. Therefore the incidence varies between different studies. Approximately, 9-25% of patients with lung cancer, 2-15% of all patients with breast cancer and 15-25% of patients with melanoma will develop leptomeningeal metastases^{1,5}.

Adenocarcinoma and small cell carcinoma of the lung are frequently seen with leptomeningeal carcinomatosis^{1,2,5,6}. Leptomeningeal metastasis of squamous cell lung cancer is extremely rare. As far as we are aware, only one case is reported⁷ except ours.

The tumor cells could reach the leptomeninges by several mechanisms: Arterial route (in patients with disseminated cancer, the leptomeninges are infiltrated through arachnoid vessels or choroid plexus); direct extension of the leptomeninges or seeding (primary CNS tumors), growing around and along peripheral nerves to the subarachnoid space (systemic tumors), iatrogenic (seeding of subarachnoid space during surgical extirpation of intraparenchymal metastases), entry to the subarachnoid space through the venous plexus of Batson and perivenous spread from adjacent bone marrow metastases. In most cases of breast or lung cancer pure leptomeningeal carcinomatosis is the result of cancer propagation from vertebral or paravertebral metastases^{1-4,9}. New metastatic deposits along meningeal surfaces which invade subpial parenchyma, penetrate spinal nerve roots, and produce masses in the subarachnoid space.

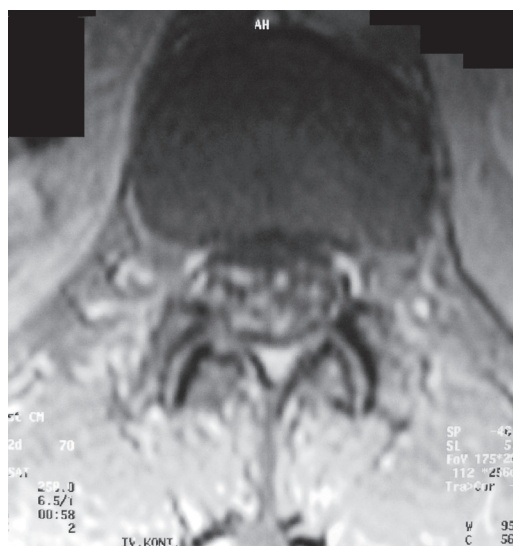

Fig. 2 – Transverse T1-weighted gadolinium-enhanced MRI scan at the L1-2 level. Enhancement of the cauda equina fibers in the thecal sac is seen

The most frequently affected regions of the CNS are the basilar cisterns, the posterior fossa, and the cauda equina where slow CSF flow and gravity promote the deposition of circulating cells¹.

Most patients with leptomeningeal metastases have widely disseminated cancer. As systemic therapy improves, progression of disease within the central nervous system becomes an increasing problem. 33-75% of patients with neoplastic meningitis had synchronous intraparenchymal brain metastases^{1,2}. The clinical presentation of leptomeningeal metastases usually involves spinal cord symptoms that attributed to radiculopathy at the involved level, lumbosacral region which is particularly common. Paralysis and vesicorectal disturbance may result from intracranial lesions, and thus it is often difficult to distinguish between the conditions of spinal origin and those of intracranial origin. However, clinical signs and symptoms of leptomeningeal metastases may be absent or may underestimate the extent of macroscopic disease^{1,2,9}.

Gadolinim-enhanced MRI is the standart and most sensitive radiological technique when leptomeningeal metastasis is suspected^{4,10}. The entire imaging of the neuraxis is mandatory because up to 50% of patients have multi-level disease, which has a poorer prognosis than single site involvement^{5,10}. The imaging features of spinal leptomeningeal metastasis on MRI are: Intradural enhancing nodules in spinal canal, spinal linear enhancement, Spinal cord enlargement and the asymmetry of the roots^{4,7,12}. High-signal metastatic lesions on T2 imaging may contrast poorly with similarly intense marrow fat, and this sequence should not be exclusively relied on for lesion detection¹⁰. In the contrary the metas-

tatic nodules of our patient were visible on unenhanced MR scans, they were hypointense on T2-weighted images which is bounded to the high mitotic activity in the masses. Diagnostic imaging together with CSF cytology provides useful information, but repeated examinations may be necessary to establish the diagnosis. A raised cell count, increased protein levels, increased levels of lactate dehydrogenase in the CSF when compared with serum levels are all suggestive of leptomeningeal disease, even when cytology is negative. It is important to perform MRI before CSF examination to avoid lumbar puncture-induced gadolinium enhancement of the arachnoid, which may last for weeks to months. This enhancement can easily be mistaken for leptomeningeal disease^{4,5}.

The treatment of leptomeningeal metastasis is palliative because eradication of tumor from the subarachnoid space with existing therapy is extremely rare^{1,10}. The metastasis of systemic cancers usually occurs in the terminal phase of illness. The median survival among patients with leptomeningeal metastasis located in the spinal cord was 2.4 months¹³. The goals of treatment in patients with leptomeningeal metastases are to relieve symptoms, improve or stabilize the neurologic status of the patient, and prolong survival^{1,2}. Despite these measures the prognosis is poor, with a median survival of 2-3 months, and focal neurologic dysfunctions do not improve in most cases. Treatment is usually with external beam radiotherapy, systemic chemotherapy, and intrathecal chemotherapy with methotrexate, thiopeta, and cytarabine¹³. Although surgery is indicated in neurological deficit, spinal instability and radiation treatment failure^{10,13}.

As a conclusion, spinal leptomeningeal metastasis is extremely rarely seen in squamous-cell lung cancer. Contrast-enhanced MR imaging is useful in the diagnosis of pial spread of metastatic disease in patients with a known primary malignancy and unexplained neurologic signs or symptoms.

References

1. Grossman SA, Krabak MJ. Leptomeningeal carcinomatosis. *Cancer Treat Rev* 1999; 25: 103-19.
2. O'Meara WP, Borkar SA, Stambuk HE, Lymberis SC. Leptomeningeal metastasis. *Curr Probl Cancer* 2007; 31:367-424.
3. Seute T, Leffers P, ten Velde GP, Twijnstra A. Leptomeningeal metastases from small cell lung carcinoma. *Cancer* 2005 ;104:1700-5.
4. Taillibert S, Laigle-Donadey F, Chodkiewicz C, Sanson M, Hoang-Xuan K, Delattre JY. Leptomeningeal metastases from solid malignancy: a review. *J Neurooncol* 2005; 75:85-99.
5. Kaal EC, Vecht CJ. CNS complications of breast cancer: current and emerging treatment options. *CNS Drugs* 2007; 21:559-579.
6. Kuwahara H, Yamada T, Yuba T, Kono K, Hosogi S, Osugi S, Nagata K, Yokomura I, Iwasaki Y. Spinal cord metastases in lung cancer: a clinical review of four cases. *Nihon 5. Kokyuki Gakkai Zasshi* 2005; 43: 296-301 (Abs).
7. Stark RJ, Henson RA, Evans SJ. Spinal metastases. A retrospective survey from a general hospital. *Brain* 1982; 105: 189-213.
8. Kizawa M, Mori N, Hashizume Y, Yoshida M. Pathological examination of spinal lesions in meningeal carcinomatosis. *Neuropathology* 2008; 28; 295-302.
9. Kokkoris CP. Leptomeningeal carcinomatosis: How does cancer reach the pia-arachnoid? *Cancer* 1983; 51: 154-160.
10. Komori T, Delbeke D. Leptomeningeal carcinomatosis and intramedullary spinal cord metastases from lung cancer: detection with FDG positron emission tomography. *Clin Nucl Med* 2001; 26: 905-907.
11. Abdi S, Adams CI, Foweraker KL, O'Connor A. Metastatic spinal cord syndromes: imaging appearances and treatment planning. *Clin Radiol* 2005; 60: 637-47.
12. Lim V, Sobel DF, Zyroff J. Spinal cord pial metastases: MR imaging with gadopentate dimeglumine. *AJNR* 1990; 11; 975-82.
13. Sakai M, Ishikawa S, Ito H, Ozawa Y, Yamamoto T, Onizuka M, Sakakibara Y. Carcinomatous meningitis from non-small-cell lung cancer responding to gefitinib. *Int J Clin Oncol* 2006;11:243-5.