

# The role of sodium thiosulphate in the treatment of calciphylaxis

James R Smith, Mark D Findlay, Colin C Geddes, Jonathan G Fox

Glasgow Renal and Transplant Unit, Western Infirmary, Glasgow, UK

Received for publication: 18/10/2012

Accepted: 08/11/2012

## ABSTRACT

Calciphylaxis is a rare but important cause of severe morbidity, which predominantly affects patients with advanced chronic kidney disease. It is associated with mortality in excess of 50% at one year, and this has changed little over the last 20 years despite advances in our understanding of its underlying pathophysiology, and evolving treatment strategies. Sodium thiosulphate has played a prominent role in the treatment of calciphylaxis since its first use in 2004, with reports of success both in improving the severe pain associated with the condition and in the healing of calciphylaxis lesions. The literature documenting the use of sodium thiosulphate in the treatment of calciphylaxis is reviewed here, along with a detailed summary of case reports and case series. While there is reason to be optimistic with regard to the efficacy of sodium thiosulphate within a multifaceted and multidisciplinary approach to treatment, there is clearly much yet to be learned.

### Key-Words:

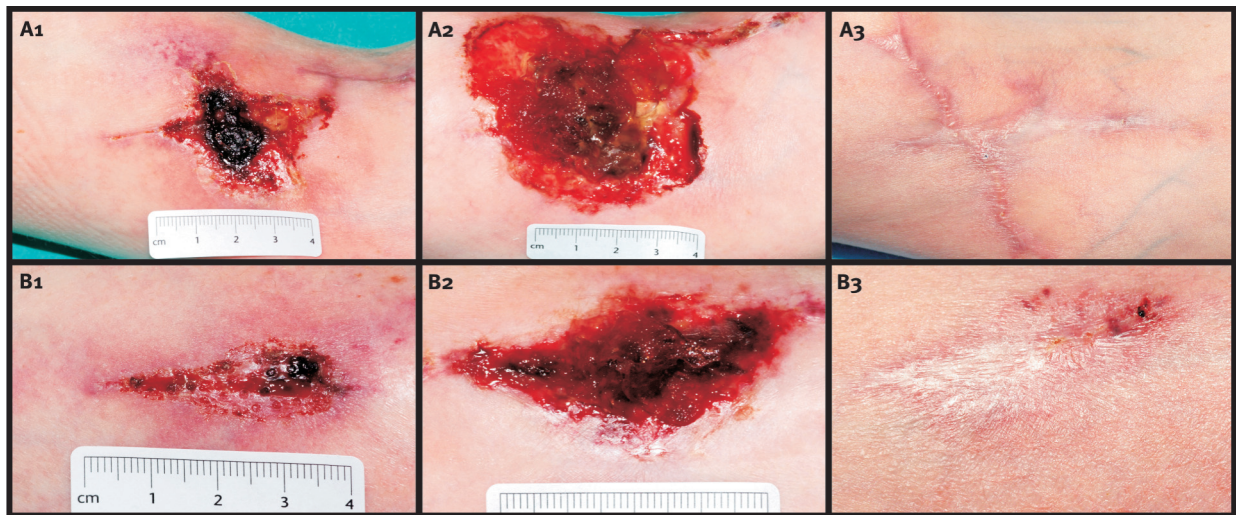
Calcific uraemic arteriopathy; calciphylaxis; sodium thiosulphate.

## INTRODUCTION

Calciphylaxis, also known as Calcific Uraemic Arteriopathy (CUA), is a rare, severe and indeed often fatal skin condition associated predominantly, but not exclusively, with dialysis-dependent chronic

kidney disease (CKD 5D). Its prevalence more than a decade ago was found to be approximately 4% in two case series of dialysis patients; however more recent data has suggested a prevalence of less than 1%<sup>1-3</sup>. Consensus has yet to be reached about the nomenclature of this condition, and there are problems with both of those mentioned above. Calciphylaxis, a portmanteau term combining calcium and anaphylaxis, was coined by Seyle in the 1960s when he found that inducing hyperparathyroidism or hypervitaminosis D in rats could 'sensitise' them to the development of soft tissue calcification when exposed to trauma or metallic salts<sup>4</sup>. The name was subsequently given to the syndrome of painful skin lesions associated with intimal vessel calcification increasingly being recognised in patients with CKD 5D and described in case reports later in the decade. More recently, given that hypersensitivity or IgE release is not implicated, CUA was proposed as a better description of the underlying pathological process. However, this is also problematic given the growing number of case reports of the condition in patients without renal failure<sup>5</sup>. 'Calciphylaxis' currently predominates both in the recent literature and in routine clinical use.

Calciphylaxis is characterised clinically by exquisitely painful, violaceous skin lesions, most commonly affecting the lower limbs or trunk<sup>6</sup>. The lesions tend to progress and enlarge rapidly from subcutaneous plaques, purpura or livedo reticularis in the early stages through to frank skin necrosis with deep, non-healing ulcers<sup>7</sup> (Figure 1). The development of calciphylaxis is associated with a marked increase in mortality, with median survival from date of



**Figure 1**

27 year old female with a background of congenital renal hypoplasia, on renal replacement therapy since 1998 (variously PD, renal transplant and most recently HD). History of secondary hyperparathyroidism and had been on cinacalcet for a number of years with good control of PTH. Failed left radiocephalic fistula creation January 2012, followed by left brachiobasilic fistula (BBF) creation in March 2012, at which point warfarin was started to preserve fistula patency. Subsequently presented with severe pain and breakdown of the brachiobasilic surgical wound (A1), and also breakdown and necrosis of the previously healed radiocephalic fistula wound (B1). Calciphylaxis diagnosed clinically (biopsy taken, but only necrotic tissue sampled therefore not diagnostic). Treatment included stopping warfarin and vitamin D and increasing the dose of noncalcium containing phosphate binder and cinacalcet. Dialysis was increased to six weekly sessions, and cinacalcet introduced at a starting dose of 25g IV three times/week, then reduced to 12.5g IV three times/week due to nausea. The BBF was ligated in May (After A2/B2 were taken) with debridement of the wound. Photographs taken from the left antecubital fossa (A1-3) and mid forearm (B1-3) on 17/4/2012 (A1/B1), 14/5/2012 (A2/B2) and 30/8/2012 (A3/B3).

diagnosis of 2.64 months (range 0-7 years) and 45.8% 1-year survival in a retrospective study of 64 patients published in 2007<sup>6</sup>.

A retrospective review of cases of calciphylaxis was recently undertaken in our unit, which provides renal services for a population of around 1.5 million. Between 02/04/2001 (when there were 486, 147 and 790 prevalent haemodialysis, peritoneal dialysis and transplant patients respectively attending our centre) and 29/05/2012 (when there were 644, 51 and 841 prevalent haemodialysis, peritoneal dialysis and transplant patients), a period of just over 11 years, 39 cases of calciphylaxis were identified using the electronic patient record. Only 7 patients remain alive. In 32, sufficient data is available to calculate a median survival from date of diagnosis to death of 39 days (range 4-976 days), and 6-month and 1-year survival of 37.5% and 31.25% respectively. Calciphylaxis was documented as directly contributing to death in 83.3%, sepsis in 37.5%, and withdrawal from dialysis in 20.8% (unpublished data).

The severity of skin involvement at presentation has been shown to influence survival, with 1-year mortality reported to increase from 41% in those with subcutaneous plaques to 67% if the skin was ulcerated. Furthermore, the subsequent development of ulceration increased mortality to over 80% at one year. While these figures are taken from a case control study of 36 patients published in 2002<sup>2</sup>, which was before the routine use of some newer therapeutic modalities, more recent reports have failed to show a significant improvement in mortality<sup>8,9</sup>. With regard to location of lesions (proximal or distal to the knee/elbow), it has been suggested that proximal lesions confer a higher risk of mortality, though Weenig et al. found no significant difference in mortality based on position of lesions in a retrospective review of 64 patients with calciphylaxis diagnosed between 1992 and 2002<sup>6</sup>. The loss of the protective epidermis/dermis layer substantially increases the risk of cutaneous and thereafter systemic infection; sepsis being documented as a contributing factor to death in 41% of cases, which is similar to our findings.

## ■ PATHOPHYSIOLOGY

Typical histological findings include small and medium-sized vessel microcalcification (best seen using the von Kossa stain), dermal and subcutaneous inflammation, microvascular thrombi and endovascular fibroblastic proliferation<sup>7</sup>. Vascular and extravascular calcification is a common consequence of chronic kidney disease (CKD) and secondary hyperparathyroidism, but only a minority of patients with such metastatic calcification will develop calciphylaxis. A number of inhibitors of vascular calcification have been identified which may be important, including fetuin-A and matrix GLA protein (MGP). Knockout mouse models for genes expressing fetuin-A and MGP exhibit extensive vascular and ectopic calcification<sup>10,11</sup>. Interestingly fetuin-A is down-regulated in inflammatory states, and inflammation is thought to play an important role in the development of calciphylaxis.

With regard to MGP, its activation is reliant upon vitamin K. Therefore coumarins such as warfarin, which inhibit the activation of vitamin K, consequently reduce the activity of MGP. Furthermore, chronic warfarin use has been associated with vascular calcification in human studies<sup>12,13</sup>. Warfarin, as well as hypoalbuminaemia (which can be a marker of inflammation) was found to be significantly associated with calciphylaxis in a recent retrospective case control study from Japan<sup>14</sup>. This study attributed less significance to some of the previously described risk factors (Table I). However, it remains likely that the aetiology is multifactorial, with uncontrolled hyperparathyroidism and elevated serum calcium $\times$ phosphate product, activation of

inflammatory mediators, protein deficiency states and medication such as warfarin, calcium supplements and vitamin D analogues all being important to varying degrees. It has been suggested that one or more of these stimuli may trigger the activation of nuclear factor kappa-B, which plays a role in bone mineralisation, atherosclerosis and growth factor activation, among other functions, and may therefore be an important step in the development of microvascular calcification<sup>15</sup>.

More recently, retrospective review of biopsy specimens has identified deposits of iron within calciphylaxis lesions, predominantly within the wall of affected vessels, with no iron seen in unaffected areas<sup>16</sup>. Deposits of aluminium and gadolinium have also been noted<sup>17</sup>. Gadolinium was not only found in specimens where the pathological diagnosis was both calciphylaxis and nephrogenic systemic fibrosis, but also in specimens where the sole pathological diagnosis was calciphylaxis. The significance of metal deposition within calciphylaxis lesions is uncertain, but these findings have led some investigators to consider iron supplementation as a potential disease trigger or risk factor, and desferrioxamine has been used as an alternative to sodium thiosulphate (STS) as a chelating agent<sup>18</sup>.

## ■ DIAGNOSIS

Clinical suspicion should be aroused when assessing any patient with CKD and secondary hyperparathyroidism who develops skin lesions associated with severe pain. The pain can be exacerbated by haemodialysis, presumably related to relative hypoperfusion and ischaemia<sup>19</sup>. While late-stage calciphylaxis lesions with ulceration and necrosis are usually typical, early lesions (for example subcutaneous nodules with no overlying skin inflammation) can be nonspecific and more difficult to recognise clinically. Most senior nephrologists and dermatologists will be familiar with the condition, while it may be completely unknown to other specialists. This may be important, for example, following surgical procedures in patients with CKD being cared for outside a specialist renal ward, when failure of wound healing and the development of tissue necrosis might not initially be recognised as calciphylaxis.

**Table I**

Potential Risk Factors for the Development of Calciphylaxis

Hyperparathyroidism
High serum calcium $\times$ phosphate product
High serum phosphate
High serum alkaline phosphatase
Female sex
Diabetes mellitus
Obesity
Protein malnutrition
Inflammation
Warfarin/Vitamin K deficiency
Protein C/Protein S deficiency

The histological findings described above are very characteristic, but not pathognomonic, of calciphylaxis. There is variation in clinical practice with regard to seeking histological confirmation given the concern that biopsy of the lesions, particularly in the early stages, can provoke ulceration and thereby worsen outcome<sup>2,3,10</sup>. On the other hand, it is important not to overlook other conditions, the cutaneous manifestations of which may resemble calciphylaxis, but which require different treatment (Table II)<sup>3,20,21</sup>.

Bone scintigraphy has been used as an aid to the diagnosis of calciphylaxis, and also to monitor response to treatment. Characteristically, there will be increased uptake of tracer within subcutaneous tissues, usually corresponding to the clinical location of lesions, although the sensitivity and specificity of this test has not been fully characterised<sup>2,22,23</sup>.

**Table II**

Differential Diagnoses

Nephrogenic systemic fibrosis
Necrotising vasculitis
Pyoderma gangrenosum
Herpes zoster infection
Cryoglobulinaemia
Ischaemic or atheroembolic peripheral vascular disease
Hypercoagulability
Coumarin necrosis

## ■ TREATMENT

Given the relative rarity of the condition and uncertainty about aetiology, treatment strategies are based upon case reports or case series reporting success in calciphylaxis. They have been aimed at correcting or removing underlying reversible risk factors or addressing theoretical targets. There are no randomised controlled trials of current treatment strategies, and it is unlikely that there ever will be. Patients in most of the published case reports have received a number of different treatments making it difficult to know which, if any, has been effective. Also, as would be expected, significant publication bias exists, and there are very few case reports detailing treatment failure.

With the above limitations in mind, many authorities advocate a multifaceted approach to the treatment of calciphylaxis. Therefore, while STS is the focus of this review, it is important to highlight the other treatment strategies commonly employed. Medication that may provoke or worsen the condition should be stopped, particularly warfarin and calcium-containing phosphate binders, as well as vitamin D analogues, although in some case reports vitamin D analogues have been continued, or started, in an effort to control hyperparathyroidism<sup>24</sup>. Vitamin K supplementation may be considered, particularly in those patients in whom warfarin is a potential trigger.

In order to optimise calcium and phosphate balance, noncalcium containing phosphate binders such as sevelamer or lanthanum are often employed. For similar reasons, in those with CKD 5D the dose of dialysis is increased where possible – peritoneal dialysis patients are often switched to haemodialysis, and the frequency of haemodialysis is increased from the standard three times weekly to up to daily dialysis. A low calcium or calcium-free dialysate is often used<sup>25</sup>.

Hyperparathyroidism is another treatment target. Urgent parathyroidectomy has been used with some reported success, perhaps related to the dramatic fall in serum calcium and phosphate sometimes seen after this procedure (the ‘hungry bones’ phenomenon), but no survival benefit was found in a retrospective case review<sup>6</sup>. More recently, calcimimetics have been used as an alternative, or as a bridge, to parathyroidectomy. These can be very effective at reducing serum parathyroid hormone, as well as calcium and phosphate levels, and there are case reports of successful resolution of calciphylaxis following the introduction of cinacalcet<sup>26–28</sup>. However, there are also reports of calciphylaxis not responding to cinacalcet<sup>29</sup>, or developing in patients already being treated with this drug<sup>30</sup>, sometimes with adequate biochemical control of hyperparathyroidism<sup>31</sup>.

There have been promising reports of success using bisphosphonates, which reduce serum calcium levels by inhibiting osteoclastic activity and possibly preventing osteoblast apoptosis, as well as by inhibiting hydroxyapatite formation *in vitro*<sup>32–34</sup>. There are concerns regarding the safety of bisphosphonates in advanced CKD, but, given the grave prognosis

associated with uncontrolled calciphylaxis, their use may be considered to be justified. Hyperbaric oxygen therapy has been advocated in order to promote wound healing, with reported success in case series<sup>35,36</sup>. However, its widespread use is hampered by cost, availability, and practicality. Prednisolone has also historically been used in the treatment of calciphylaxis. While there may be some benefit in the early stages, it is not recommended in the presence of ulcerated lesions, the increased infection risk being a major concern<sup>2</sup>.

In addition to the above strategies, an emphasis on good wound care, surgical debridement of necrotic lesions (which has been shown to be associated with a survival benefit)<sup>6</sup>, and prompt use of antibiotics for bacterial infection are also likely to play an important role in improving the chances of healing calciphylaxis lesions.

## ■ SODIUM THIOSULPHATE (STS)

STS has been used as a therapeutic agent in medicine for over a century. It is a reducing and antioxidant agent, and has been described as a chelator of cations, although strictly speaking this is incorrect as it does not bind ions at more than one site<sup>37,38</sup>. It was first used as an antidote for cyanide poisoning, for which it remains a third-line treatment to this day<sup>39-41</sup>. In the middle of the twentieth century, STS was investigated as a potential agent to measure glomerular filtration rate (GFR) and extracellular fluid volume<sup>42,43</sup>. However, it does not provide a reliable measure of GFR as it is produced endogenously and has significant and variable non-renal elimination<sup>44</sup>. STS has also been used in oncology, both as an antidote for extravasation injury, and a means of preventing the ototoxicity and nephrotoxicity associated with platinum-based chemotherapies<sup>45,46</sup>.

### ■ Sodium Thiosulphate in Vascular and Extra-Vascular Calcification

STS administration has been reported to reduce urinary tract stone formation in stone formers compared with a control period during which the same patients were treated with adequate oral hydration

alone<sup>47</sup>. It was postulated that this effect was the result of the high solubility of calcium thiosulphate in urine. STS was subsequently shown to reduce extravascular or tumoural calcification in dialysis patients<sup>48,49</sup>.

These results led to the idea that the microvascular calcification seen in calciphylaxis might be improved by STS. In 2004, the first case report of successful use of STS in a patient with calciphylaxis was published<sup>50</sup>. The clinical finding of subcutaneous plaques seemingly melting away following treatment gave weight to the idea that calcium salts were being dissolved by STS<sup>19</sup>. Subsequently, uraemic rats treated with STS were found to be protected from the development of aortic calcification, with an increase in urinary calcium excretion and development of metabolic acidosis noted<sup>51</sup>. Also, in a recent study comparing 16 haemodialysis patients treated with intravenous (IV) STS versus 16 controls matched for coronary artery calcification scores over 4-months, progression of coronary artery calcification was prevented in those treated with STS<sup>52</sup>.

It has been suggested that STS has potent antioxidant and vasodilator properties, which could provide an explanation for the rapid pain relief described following STS treatment of calciphylaxis<sup>53,54</sup>. However, recent laboratory work studying STS and vascular calcification has cast doubt on some of these ideas<sup>38</sup>. While STS does appear to inhibit the calcification of injured or devitalised aortic tissue in vitro through direct extracellular actions, this is not specific for the thiosulphate salt, being seen also with sodium sulphate. The solubility of calcium sulphate is much lower than that of calcium thiosulphate, suggesting that increased solubility of calcium thiosulphate is not likely the reason for the beneficial effects of STS. Additionally, the antioxidant effect was challenged given that sulphate is the terminal oxidation phase of sulphur. It was also noted that STS did not inhibit hydroxyapatite formation in vitro.

While the mechanisms of its action remain unclear, interest in STS has flourished since 2004. We have identified 61 published case reports (including some small retrospective case series and conference abstracts) of STS in the treatment of calciphylaxis. Most of these document treatment success, with rapid resolution of pain within days or weeks, often

**Table III**

Case reports of calciphylaxis or calcific ur(a)emic arteriopathy treated with sodium thiosulphate.

2004-2012

61 cases in 34 publications (including case series/conference abstracts); where data was not available for all patients, number of patients is stated.

Patient details		Treatment & outcome details	
<b>Baseline Characteristics</b>		<b>Sodium Thiosulphate</b>	
Mean age (range)	52 years (12-83)	Mean duration of treatment (n=32), (range)	13.7 weeks (0.3-80)
Female	73.8%	<b>Other treatments used</b>	
Diabetes mellitus	45.9%	Increased dialysis dose/freq. (n=38)	73.7%
Previous parathyroidectomy	11.5%	Low Ca <sup>2+</sup> /Ca <sup>2+</sup> free dialysate (n=29)	79.3%
Taking Warfarin at diagnosis	31.1%	NCCPB (n=36)	69.4%
Mean serum Ca <sup>2+</sup> (n=32)	2.42 mmol/L	Cinacalcet (n=47)	42.6%
Mean serum PO <sub>4</sub> <sup>4-</sup> (n=31)	2.01 mmol/L	Parathyroidectomy	13.6%
Mean serum Ca <sup>2+</sup> ×PO <sub>4</sub> <sup>4-</sup> (n=31)	4.87		
Plasma PTH >300 pg/ml or >100 pmol/L (n=40)	33.3%		
Mean serum albumin (n=14)	26.9 g/L		
<b>Incident RRT Status</b>		<b>Outcome</b>	
Haemodialysis	52.5%	<i>Pain relief</i>	
Peritoneal dialysis	31.1%	Yes	68.9%
Transplant (failing)	1.6% (1 patient)	No	8.2%
Chronic kidney disease	6.6%	Unknown	22.9%
Normal renal function	8.2%		
RRT Vintage in months (range) (n=29)	68.5 (1-360)	<i>Healing/stability of lesions</i>	
		Yes	82.0%
		No	16.4%
<b>Calciphylaxis Lesions</b>		Unknown	1.6% (1 patient)
Ulcerated	71.2%		
Biopsy confirmed	67.8%		

References: 8,18,19,22,24,27-31,50,54-76

Pain relief was not explicitly stated as an outcome in a number of reports (hence pain relief &lt; healing), but it is likely to have accompanied healing in most cases.

PTH – parathyroid hormone; RRT – renal replacement therapy; NCCPB – non-calcium containing phosphate binder; Rx – treatment.

supported by impressive reductions in requirements for analgesia. Cessation of new lesion formation along with complete or partial wound healing or reduction in the size of subcutaneous plaques is also commonly reported. Table III summarises the cases and results published to date.

Although the case reports overwhelmingly document treatment success, it is difficult to attribute this directly to STS treatment for reasons previously described. In earlier cases, STS was often used as a final adjunct after several other treatment options had been trialled unsuccessfully. These treatments were usually continued while STS was being administered. It is often impossible to identify exactly how long after diagnosis, or how long after previous trials of treatment, STS was started in the case reports. More recently, STS has been used earlier in the course of treatment, but again, only as one of a

number of changes to management instituted at the time of diagnosis. One case report goes some way towards substantiating the efficacy of STS, describing the recurrence of pain and early calciphylaxis lesions 1-month after the end of a 3-month course of STS. STS was restarted, and there followed a similar swift resolution of pain and healing of lesions. The treatment was continued for 8-months, with no further recurrence after 18-months follow-up<sup>60</sup>.

Despite their unavoidable weaknesses, the published retrospective case series are likely to be subject to less publication bias than individual case reports. While not being able to draw direct conclusions about the benefits or otherwise of STS in the treatment of calciphylaxis, it is interesting to note that patient survival in these studies is broadly similar to that reported prior to the routine use of STS and other more recent treatments (Table IV).

**Table IV**

Outcome data for case series of patients with calciphylaxis.

<b>A) Case series (with &gt;3 patients) of patients treated with sodium thiosulphate</b>								
	Year	No. of patients	Study Period	Mean Age (yrs)	Female (%)	Healed (%)	6-month survival (%)	1-year survival (%)
Baldwin C et al <sup>18*</sup>	2011	7	2007-2010	65.1	85.7	85.7	85.7	71.4
Noureddine et al <sup>8</sup>	2011	14	2003-2007	49.3	71.4	71.4	50	28.6
Sood et al <sup>28</sup>	2011	6	2006-2008	49.7	83.3	66.7	50	50
<b>B) Larger case series where sodium thiosulphate was not used (for comparison)</b>								
Fine et al <sup>2</sup>	2002	36	1994-2001	54	75	ns	61	55
Weenig et al <sup>6</sup>	2007	63	1992-2002	59	83	ns	2.64 months (median survival)	45.8

\*one patient improved initially with STS, but switched to desferrioxamine (iron chelating agent) because of nausea (survivor)

ns – not stated

## ■ Dosing of Sodium Thiosulphate

The first report of STS in calciphylaxis by Cicone et al. used STS at a dose of 25g IV three times per week<sup>50</sup>. The reasons for choosing this dose were not specifically described, but reflect historical dosing for other indications. Most case reports have used a similar dosing regime, with the drug being given at the end of dialysis as an infusion over 30-60 minutes. This seems to be tolerated well, with the need for dose reduction being reported infrequently.

STS is predominantly excreted by the renal route, and during dialysis is removed by diffusion. Singh *et al.* devised a mathematical model to predict dose requirements for different modalities, doses and frequencies of haemodialysis, with the assumption that extracorporeal clearance of STS is similar to that of creatinine, given their similar molecular weights (158.11 vs. 113.12 Da)<sup>77</sup>. Using this model, if a total weekly dose of 75g STS IV is taken as effective in patients on haemodialysis for 4 hours, 3 times a week, an increase in the total weekly dose would be required to ensure a similar area under the concentration-time curve if dialysis frequency or dialysis dose is increased – up to a total of 90g STS weekly (in divided doses) for 2.5 hours haemodialysis five times a week, and much higher doses for continuous venovenous haemodialysis.

There is no clear guidance about the appropriate duration of therapy, but most suggest continuing

at least until lesions have healed completely, and the course is often extended for several weeks or months thereafter in an effort to prevent recurrence<sup>60</sup>. The mean treatment duration was 13.9 weeks (range 0.3-80 weeks) in the case reports referenced (Table III).

## ■ Side Effects of Sodium Thiosulphate

The most prominent side effect reported with STS is nausea and vomiting, and is usually described as mild, temporally related to the infusion, and responsive to antiemetics and/or prokinetics. Reducing the dose or rate of infusion can be helpful. A raised anion gap metabolic acidosis is also well recognised, and can be severe<sup>78</sup>. This is again less of a problem with a reduced dose, but is also relatively easily managed with bicarbonate supplementation or increasing the dialysate bicarbonate. Headache, hypotension, thrombophlebitis (when STS is given through a peripheral IV cannula), and hypersensitivity to smells with anorexia have been reported<sup>19,54,59,67</sup>. One patient developed five beats of broad complex tachycardia during STS infusion, which did not recur<sup>64</sup>.

With regard to longer-term adverse effects, there is some concern over the possibility of bone demineralisation, with a reduction in bone strength/bone mineral density (BMD) compared with controls reported in both animal and human studies of STS<sup>51,52</sup>. Adirekkiat *et al.* demonstrated a significant

reduction in total hip BMD and a trend towards a reduction in lumbar spine BMD in patients treated with 12.5g IV STS twice weekly for 4-months:- a much smaller dose than is usually given in the treatment of calciphylaxis. The reason for this is unclear, but the metabolic acidosis induced by STS treatment could be a contributing factor. This may be clinically relevant in longer-term survivors of calciphylaxis.

## ■ SUMMARY

Calciphylaxis, while rare, is associated with severe morbidity and mortality. Over the last decade, significant advances have been made in understanding its underlying pathophysiology, but newer data appear to be dispelling previously accepted theories, and clearly more remains to be discovered. A low index of suspicion, early diagnosis, and a multifaceted approach to treatment is to be recommended in order to provide the optimum conditions to allow healing, and this has led to some success. STS, when used as part of this type of treatment strategy, appears to improve pain, and thereafter wound healing, but does not definitely improve mortality. Arguably, however, the swift and often complete relief of otherwise intractable pain achieved with STS treatment, along with its favourable side effect profile, appears reason enough to justify its use even when the extent and severity of calciphylaxis lesions and the overall condition of the patient make the situation apparently unsalvageable.

In order to improve the evidence base, well-designed multi-centre therapeutic trials on a scale large enough to be clinically useful would be the ideal, although it seems unlikely that this will be achievable. The UK Calciphylaxis Study is currently recruiting, with the aim of providing epidemiological insights<sup>79</sup>. There are also national and international calciphylaxis registries, for example The UK Calciphylaxis Registry<sup>80</sup> and Deutsches Calciphylaxie Register<sup>81</sup> which, with sufficient participation, should help to guide future treatment strategies and improve our understanding of this challenging disease.

**Conflicts of interest statement.** None declared.

## References

1. Angelis M, Wong LL, Myers SA, Wong LM. Calciphylaxis in patients on hemodialysis: a prevalence study. *Surgery* 1997;122(6):1083–1089
2. Fine A, Zacharias J. Calciphylaxis is usually non-ulcerating: Risk factors, outcome and therapy. *Kidney Int* 2002;61:2210–2217
3. Brandenburg VM, Cozzolino M, Ketteler M. Calciphylaxis: a still unmet challenge. *J Nephrol* 2011;24(2):142–148
4. Seyle H. *Calciphylaxis*. Chicago, Ill: University of Chicago Press; 1962
5. Nigwekar SU, Wolf M, Sterns RH, Hix JK. Calciphylaxis from nonuremic causes: a systematic review. *Clin J Am Soc Nephrol* 2008;3(4):1139–1143
6. Weenig RH, Sewell LD, Davis MDP, McCarthy JT, Pittelkow MR. Calciphylaxis: natural history, risk factor analysis, and outcome. *J Am Acad Dermatol* 2007;56(4):569–579
7. Essary LR, Wick MR. Cutaneous calciphylaxis. An underrecognized clinicopathologic entity. *Am J Clin Pathol* 2000;113(2):280–287
8. Noureddine L, Landis M, Patel N, Moe SM. Efficacy of sodium thiosulfate for the treatment of calciphylaxis. *Clin Nephrol* 2011;75(6):485–490
9. Malabu UH, Manickam V, Kan G, Doherty SL, Sangla KS. Calcific uremic arteriopathy on multimodal combination therapy: still unmet goal. *Int J Nephrol* 2012;2012:1–6
10. Wilmer WA, Magro CM. Calciphylaxis: Emerging concepts in prevention, diagnosis, and treatment. *Semin Dialysis* 2002;15(3):172–186
11. Rogers NM, Teubner DJO, Coates PTH. Calcific uremic arteriopathy: advances in pathogenesis and treatment. *Semin Dialysis* 2007;20(2):150–157
12. Rennenberg RJMW, van Varik BJ, Schurgers LJ, et al. Chronic coumarin treatment is associated with increased extracoronary arterial calcification in humans. *Blood* 2010;115(24):5121–5123
13. Schurgers LJ, Joosen IA, Laufer EM, et al. Vitamin K-antagonists accelerate atherosclerotic calcification and induce a vulnerable plaque phenotype. *PLoS one* 2012;7(8):1–14
14. Hayashi M, Takamatsu I, Kanno Y, Yoshida T, Abe T, Sato Y. A case-control study of calciphylaxis in Japanese end-stage renal disease patients. *Nephrol Dial Transplant* 2012;27(4):1580–1584
15. Weenig RH. Pathogenesis of calciphylaxis: Hans Selye to nuclear factor kappa-B. *J Am Acad Dermatol* 2008;58(3):458–471
16. Farah M, Crawford R, Levin A, Yan C. Calciphylaxis in the current era: emerging “ironic” features? *Nephrol Dial Transplant* 2011;26:191–195
17. Amuluru L, High W, Hiatt KM, et al. Metal deposition in calcific uremic arteriopathy. *J Am Acad Dermatol* 2009;61(1):73–79.
18. Baldwin C, Farah M, Leung M, Taylor P. Multi-intervention management of calciphylaxis: a report of 7 cases. *Am J Kidney Dis* 2011;58(6):988–991
19. Musso CG, Enz P, Vidal F, et al. Use of Sodium Thiosulfate in the Treatment of Calciphylaxis. *Saudi J Kidney Dis Transpl* 2009;20(6):1065–1068
20. Latus J, Kimmel M, Ott G, Ting E, Alschner MD, Braun N. Early stages of calciphylaxis: are skin biopsies the answer? *Case Reports Derm* 2011;3(3):201–205
21. Ross EA. Evolution of treatment strategies for calciphylaxis. *Am J Nephrol* 2011;34(5):460–7
22. Norris B, Vaysman V, Line BR. Bone Scintigraphy of Calciphylaxis: A Syndrome of Vascular Calcification and Skin Necrosis. *Clin Nucl Med* 2005;30(11):725–727
23. Soni S, Leslie W. Bone scan findings in metastatic calcification from calciphylaxis. *Clin Nucl Med* 2008;33(7):502–504
24. Auriemma M, Carbone A, Di L, et al. Treatment of Cutaneous Calciphylaxis with Sodium Thiosulfate Two Case Reports and a Review of the Literature. *Am J Clin Dermatol* 2011;12(5):339–346



25. Wang H, Yu C, Huang C. Successful treatment of severe calciphylaxis in a hemodialysis patient using low-calcium dialysate and medical parathyroidectomy: case report and literature review. *Renal Fail* 2004;26(1):77-82
26. Velasco N, MacGregor MS, Innes A, MacKay IG. Successful treatment of calciphylaxis with cinacalcet-an alternative to parathyroidectomy? *Nephrol Dial Transplant* 2006;21(7):1999-2004
27. Scola N, Gäckler D, Stücker M, Kreuter A. Complete clearance of calciphylaxis following combined treatment with cinacalcet and sodium thiosulfate. *J Germ Soc Dermatol* 2011;9(12):1030-1031
28. Sood A, Wazny L, Raymond C. Sodium thiosulfate-based treatment in calcific uremic arteriopathy: a consecutive case series. *Clin Nephrol* 2011;75(1):8-16
29. Ackermann F, Levy A, Daugas E. Sodium Thiosulfate as First-Line Treatment for Calciphylaxis. *Arch Dermatol* 2007;143(10):1336-1338
30. Conde Rivera O, Camba Caride M, Novoa Fernández E, et al. Multidisciplinary treatment. A therapeutic option to treat calciphylaxis. *Nefrología* 2011;31(5):614-616
31. Noten CV, Doorn KJV, Vermander E, Vlayen S, Verpooten G, Couttenye M-M. Maximal conservative therapy of calcific uremic arteriopathy. *Clin Nephrol* 2011;78(1):61-64
32. Schliep S, Schuler G, Kieseewetter F. Successful treatment of calciphylaxis with pamidronate. *Eur J Dermatol* 2008;18(5):554-556
33. Torregrosa JV, Durán CE, Barros X, et al. Successful treatment of calcific uremic arteriopathy with bisphosphonates. *Nefrología* 2012;32(3):329-334
34. Rosen H. Pharmacology of bisphosphonates. In: Bascoe D, ed. *UpToDate* Vol 49. Waltham, MA; 2012
35. Basile C, Montanaro A, Masi M, Pati G, De Maio P, Gismondi A. Hyperbaric oxygen therapy for calcific uremic arteriopathy: a case series. *J Nephrol*. 2002;15(6):676-680.
36. Rogers NM, Coates PTH. Calcific uremic arteriopathy – the argument for hyperbaric oxygen and sodium thiosulfate. *Semin Dialysis* 2010;23(1):38-42
37. Hayden MR, Tyagi SC, Kolb L, Sowers JR, Khanna R. Vascular ossification-calcification in metabolic syndrome, type 2 diabetes mellitus, chronic kidney disease, and calciphylaxis-calcific uremic arteriopathy: the emerging role of sodium thiosulfate. *Cardiovasc Diabetol* 2005;4(4)
38. O'Neill WC, Hardcastle KI. The chemistry of thiosulfate and vascular calcification. *Nephrol Dial Transplant* 2012;27(2):521-526
39. Mannaioni G, Vannacci A, Marzocca C, Zorn AM, Peruzzi S, Moroni F. Acute cyanide intoxication treated with a combination of hydroxocobalamin, sodium nitrite, and sodium thiosulfate. *Clin Toxicol* 2002;40(2):181-183
40. Hall AH, Dart R, Bogdan G. Sodium thiosulfate or hydroxocobalamin for the empiric treatment of cyanide poisoning? *Ann Emerg Med* 2007;49(6):806-813
41. Desai S, Su M. Cyanide poisoning. In: Bascoe DS, ed. *UpToDate*. Waltham, MA; 2012
42. Cardozo R, Edelman I. The Volume of Distribution of Sodium Thiosulfate as a Measure of the Extracellular Fluid Space. *J Clin Inv* 1952;3:280-290
43. Vorburger C, Reubi F. Renal clearances. Comparative studies of sodium thiosulfate and Na<sub>2</sub>Cr (Cr<sub>5</sub>) ethylenediaminetetraacetate (Cr<sub>5</sub>-EDTA) in man. *Minn Med* 1969;52(1):37-39
44. Farese S, Stauffer E, Kalicki R, et al. Sodium thiosulfate pharmacokinetics in hemodialysis patients and healthy volunteers. *Clin J Am Soc Nephrol* 2011;6(6):1447-1455
45. Payne A, Savarese D. Chemotherapy extravasation injury. In: Bascoe D, ed. *UpToDate*. Waltham, MA; 2012
46. Portilla D, Mazin Safar A, Shannon M, Penson R. Cisplatin nephrotoxicity. In: Bascoe D, ed. *UpToDate*. Vol 12. Waltham, MA; 2012.
47. Yatzidis H. Successful sodium thiosulphate treatment for recurrent calcium urolithiasis. *Clin Nephrol* 1985;23(2):63-67
48. Yatzidis H, Agroyannis B. Sodium Thiosulfate Treatment of Soft-Tissue Calcifications in Patients With End-Stage Renal Disease. *Perit Dial Int* 1987;(5):3-5
49. Papadakis J, Patrikarea A. Sodium thiosulfate in the treatment of tumoral calcifications in a hemodialysis patient without hyperparathyroidism. *Nephron* 1996;72(2):308-312
50. Cicone JS, Petronis JB, Embert CD, Spector DA. Successful treatment of calciphylaxis with intravenous sodium thiosulfate. *Am J Kidney Dis* 2004;43(6):1104-1108
51. Pasch A, Schaffner T, Huynh-Do U, Frey BM, Frey FJ, Farese S. Sodium thiosulfate prevents vascular calcifications in uremic rats. *Kidney Int* 2008;74(11):1444-1453
52. Adirekktat S, Sumethkul V, Ingsathit A, et al. Sodium thiosulfate delays the progression of coronary artery calcification in haemodialysis patients. *Nephrol Dial Transplant* 2010;25(6):1923-1929
53. Hayden MR, Goldsmith DJA. Sodium thiosulfate: new hope for the treatment of calciphylaxis. *Semin Dialysis* 2010;23(3):258-262
54. Tokashiki K, Ishida A, Kouchi M, et al. Successful management of critical limb ischemia with intravenous sodium thiosulfate in a chronic hemodialysis patient. *Clin Nephrol* 2006;66(2):140-144
55. Bruccleri M, Cheigh J, Bauer G, Serur D. Long-term intravenous sodium thiosulfate in the treatment of a patient with calciphylaxis. *Semin Dialysis* 2005;18:431-434
56. Guerra G, Shah RC, Ross EA. Rapid resolution of calciphylaxis with intravenous sodium thiosulfate and continuous venovenous haemofiltration using low calcium replacement fluid: case report. *Nephrol Dial Transplant* 2005;20(6):1260-1262
57. Meissner M, Bauer R, Beier C, et al. Sodium thiosulphate as a promising therapeutic option to treat calciphylaxis. *Dermatology* 2006;212(4):373-376
58. Araya CE, Fennell RS, Neiberger RE, Dhamidharka VR. Sodium thiosulfate treatment for calcific uremic arteriopathy in children and young adults. *Clin J Am Soc Nephrol* 2006;1(6):1161-1166
59. Baker B, Fitzgibbons C, Buescher L. Calciphylaxis Responding to Sodium Thiosulphate Therapy. *Arch Dermatol* 2007;143:269-270
60. Subramaniam K, Wallace H, Sinniah R, Saker B. Complete resolution of recurrent calciphylaxis with long-term intravenous sodium thiosulfate. *Austral J Dermatol* 2008;49(1):30-34
61. Rose R, Wilson C. The treatment of calciphylaxis with intravenous sodium thiosulphate. *J Am Acad Dermatol* 2008;P1907:AB98
62. Musso C, Enz P, Vidal F. Oral Sodium Thiosulfate Solution as a Secondary Preventive Treatment for Calciphylaxis in Dialysis Patients. *Saudi J Kid Dis Transpl* 2008;19(5):820-821
63. Hackett BC, McAleer MA, Sheehan G, Powell FC, O'Donnell BF. Calciphylaxis in a patient with normal renal function: response to treatment with sodium thiosulfate. *Clin Exp Dermatol* 2009;34(1):39-42
64. Amin N, Gonzalez E, Lieber M, Salusky IB, Zaritsky JJ. Successful treatment of calcific uremic arteriopathy in a pediatric dialysis patient. *Pediatr Nephrol* 2010;25(2):357-362
65. Robinson M, Francis M, Mawad H. 252: Calciphylaxis Case Study With Response to Sodium Thiosulfate Treatment. *Am J Kidney Dis: Spring Clinical Meetings Abstracts*. 2010;55(4):B94
66. Wagner S, El Ters M, Azodo I, Frazee E, Ellingson S, Dillon J. 343: Successful Treatment of Severe Cutaneous Calciphylaxis With High-Dose Sodium Thiosulfate. *Am J Kidney Dis: NKf* 2011 Spring Clinical Meetings Abstracts. 2011;57(4):B102.
67. Ong S, Coulson IH. Normo-renal calciphylaxis: response to sodium thiosulfate. *J Am Acad Dermatol* 2011;64(5):e82-84
68. Nuno A, Sanchez-Gilo A, Sanz Robles H, Lopez JL, Calzado L. Calciphylaxis ulcers treated with sodium thiosulfate. *J Am Acad Dermatol: Abstracts*. 2011:AB111
69. Miceli S, Milio G, La Placa S, et al. Sodium thiosulfate not always resolves calciphylaxis: an ambiguous response. *Renal failure* 2011;33(1):84-87

70. Salanova Villanueva L, Sánchez González MC, Sánchez Tomero J, Sanz P. Successful treatment with sodium thiosulfate for calcific uraemic arteriopathy. *Nefrología* 2011;31(3):366–368
71. Smith VM, Oliphant T, Shareef M, Merchant W, Wilkinson SM. Calciphylaxis with normal renal function: treated with intravenous sodium thiosulfate. *Clin Exp Dermatol* 2012;1:1–5
72. Thang OHD, Jaspars EH, ter Wee PM. Necrotizing mastitis caused by calciphylaxis. *Nephrol Dial Transplant* 2006;21(7):2020–2021
73. Tindni A, Gaurav K, Panda M. Non-healing painful ulcers in a patient with chronic kidney disease and role of sodium thiosulfate: a case report. *Cases Journal* 2008;1(178)
74. Li JZ, Huen W. Images in Clinical Medicine: Calciphylaxis with Arterial Calcification. *N Engl J Med* 2007;357(13):1326
75. Kalisiak M, Courtney M, Lin A, Brassard A. Calcific uremic arteriopathy (calciphylaxis): successful treatment with sodium thiosulfate in spite of elevated serum phosphate. *J Cutan Med Surg* 2009;13(S1):S29–S34
76. Sandhu G, Gini MB, Ranade A, Djebali D, Smith S. Penile calciphylaxis: a life-threatening condition successfully treated with sodium thiosulfate. *Am J Ther* 2012;19(1):e66–68
77. Singh RP, Derendorf H, Ross EA. Simulation-based sodium thiosulfate dosing strategies for the treatment of calciphylaxis. *Clin J Am Soc Nephrol* 2011;6(5):1155–1159
78. Selk N, Rodby RA. Unexpectedly severe metabolic acidosis associated with sodium thiosulfate therapy in a patient with calcific uremic arteriopathy. *Semin Dialysis* 2011;24(1):85–88
79. Sinha S. ICCN – International Collaborative Calciphylaxis Network. 2012. Available at: <http://www.calciphylaxis.org.uk>. Accessed October 16, 2012
80. Sinha S. The UK Calciphylaxis Registry. 2012. Available at: <http://www.renal.org/academic/UKCalciphylaxisRegistry.aspx>. Accessed October 16, 2012
81. Ketteler M, Brandenburg VM. Deutsches Calciphylaxie Register. 2012. Available at: <http://www.calciphylaxie.de>. Accessed October 16, 2012

**Correspondence to:**

Dr James R. Smith  
Glasgow Renal and Transplant Unit  
Western Infirmary, Glasgow, G11 6NT  
United Kingdom  
jsmith82@nhs.net